



Comparative Morphometrical Study of Proventriculus and Gizzard in Eurasian Collared Dove (*Streptoplia decaocto*) and Buzzard (*Beuteo beuteo vulpinus*)

Ridha Abbas Al-Musawi ^{a*} and Salim Salih Ali Al-Khakani ^a

^a Department of Anatomy and histology, College of Veterinary Medicine, Al-Qasim Green University, Babylon, 51013, Iraq.

Authors' contributions

This work was carried out in collaboration between both authors. Both authors read and approved the final manuscript.

Article Information

DOI: <https://doi.org/10.56557/upjoz/2024/v45i174387>

Open Peer Review History:

This journal follows the Advanced Open Peer Review policy. Identity of the Reviewers, Editor(s) and additional Reviewers, peer review comments, different versions of the manuscript, comments of the editors, etc are available here: <https://prh.mbimph.com/review-history/3972>

Original Research Article

Received: 16/06/2024

Accepted: 19/08/2024

Published: 23/08/2024

ABSTRACT

Background and Objective: The domestic dove, often known as the city dove or rock dove, is a subspecies of the rock dove. Domesticated birds began with the dove. The massive buzzard (*Buteo buteo*) inhabits many ecosystems across the globe. The Accipitridae family and *Buteo* genus include it. Buzzards hunt and eat alone, however, they may gather in flocks during the migration or when food is plentiful.

Aims: Comparative Morphometrical Study in Proventriculus and Gizzard in Eurasian Collared Dove (*Streptoplia decaocto*) and Buzzard (*Beuteobeuteo vulpinus*).

Materials and Methods: 7 adult healthy dove (*streptopliadecaocto*) and the same number of adult healthy common buzzard (*beuteobeuteo vulpinus*). were used in the present study, where obtained from a commercial market of AL-muthanaa city were used in the morphometrical study.

*Corresponding author: Email: ridhaabbas@vet.uoqasim.edu.iq;

Results: The proventriculus in the dove was a dark in colour with thin-wall fusiform-shaped, this tube was separated from the gizzard by an isthmus, the internal surface of the proventriculus appear shallow longitudinal folds. While in buzzard, it's a cone-shaped structure relatively with a thick and dark wall separated between the proventriculus and gizzard by an unclear isthmus, with a number of well-developed longitudinal folds called proventriculus folds. Gizzard in dove in this study revealed the gizzard usually located towards the abdomen, at the bottom of the thoracic cavity and at in abdominal inlet, between the liver lobes justly behind live left lobe and connected with the duodenum, appeared as disc or biconvex lens shape change in color from creamy to red-brown morphologically, and is lined with kaolin (keratohyalin material) that appear yellowish to green in colour, while in buzzard located dorsocaudally to liver lobes towards the abdomen cavity, at dorsal part of the thoracic cavity, between the liver lobes, behind and connected with the duodenum and appear larger than liver lobes with shapes may range from pear to elongated, depending on the bird's unique anatomy and diet lining layer has very poor yellowish green pigment inside the gizzard.

Conclusion: In general, and depending on the unique bird's anatomy and the diet programs, there are changes in the inner surface of the organs of Dove and Buzzard.

Keywords: Morphometric; morphological; gizzard; dove; proventriculus.

1. INTRODUCTION

The avian gastrointestinal tract (GIT) underwent many physiological structures compared to other animal orders. On one hand, it has evolved to take advantage of various food types' physical and chemical characteristics [1]. The digestive tract in birds is generally subdivided into the oesophagus, proventriculus, gizzard, small intestine, ceca, rectum, and cloaca. These different compartments of the gut display both morphological and functional variation between species, variation related to evolutionary history, dietary niche, seasonal factors, and other aspects of ecology [2]. The digestive systems of birds are remarkably diverse between species, according to comparative studies [3]. This variety is a result of adaptations to different food niches. As an illustration, birds that primarily eat plants typically have longer digestive tracts and specific adaptations for breaking down plant matter through fermentation, whereas birds that primarily eat meat usually have shorter and more muscular digestive systems designed to consume animal food. A bird's eating ecology and food preferences can be better understood by analyzing its oesophagus and stomach histology and shape [4-5]. The gastrointestinal tract between the oesophagus and intestine provides several vital functions, such as its direct role in digestion by secretion of acid and enzymes [6]. The stomach of a bird is anatomically composed of two parts. The first stomach is the proventriculus, which connects with the oesophagus; the second chamber, the gizzard or ventriculus, connects with the large intestine. The Gizzard stomach grinds grains

using its muscles to facilitate the digestive process [7]. The two stomach chambers are different in size and shape depending on the nature of birds' diets as carnivores, piscivorous, and granivorous birds [8].

2. MATERIALS AND METHODS

Adult healthy 7 doves (*streptoplia decaocto*) and the same number of adult healthy common buzzard (*beuteobeuteo vulpinus*). were used in the present study, where obtained from a commercial market of AL-muthanaa city were used in the morphometrical study, after total anesthesia by use of ketamine and xylazine, injection I.M, and take weight, length from all the birds with longitudinal incision was done in the mid ventral surface, the gastrointestinal tract was removed from the esophagus to the vent.

3. RESULTS AND DISCUSSION

3.1 Morphological Study of Proventriculus in Dove and Buzzard

The present work revealed that the mean ratio of proventriculus length to body length in dove was (10.4%) which is larger and differs significantly at level ($p < 0.05$) than that of buzzard (7.9%) although the mean length of proventriculus of dove about (2.30 ± 0.070) (Check word) in buzzard about (3.42 ± 0.058) cm. the result of current study showed that the mean ratio of proventriculus weight to body weight in dove was (1.4%) which is significantly higher than that ratio in buzzard was (0.40%) regardless of the

mean weight of proventriculus in dove about (2.10 ± 0.078) grams and in buzzard about (3.30 ± 0.130) grams (Tables 1,2).

3.1.1 In dove

The anatomical results showed that the stomach consisted of two distinct parts small cranial part, a proventriculus (Pars glandular), and a sizeable caudal part, a gizzard (Pars muscularis or ventriculus). proventriculus situated in the left median part of the abdominal cavity, situated just beneath the heart (Fig. 1). These results agree with [9]. The delicate, spindle-shaped proventriculus is situated just beneath the heart and spanned ventero-laterally at the rostral 2/3 of the abdominal cavity. The present study observed that the gross anatomical structure of the proventriculus appeared dark in colour with a thin-wall fusiform-shaped tube starting at the narrow end of the thoracic oesophagus in the abdominal cavity, this tube was separated from the gizzard by an isthmus. The internal surface of the proventriculus appears shallow longitudinal folds without papilla (Fig. 3). This result agrees with [10-11]. Who showed Proventriculus in *Streptopelia senegalensis aegyptiaca* is a dark, spindle-shaped tube and that is separated from the gizzard by an isthmus, has longitudinal folds, while; the proventriculus is notably smaller in granivorous birds compared to carnivorous birds according to [12-13].

3.1.2 In buzzard

The proventriculus is situated in the left median part of the abdominal cavity, situated just dorsally to the base of the heart and craniodorsally to the liver connected with esophagus cranially and with muscular stomach caudally by an unclear isthmus separated between two organs (Fig. 2). The present study observed a cone-shaped structure relatively with a thick and dark wall and there was no clear isthmus separating proventriculus from the gizzard with a number of well-developed longitudinal folds called proventriculus folds in the internal lumen of proventriculus about three to four in number and there is deep longitudinal groove separated between these folds called proventriculus grooves. there were no macroscopic papillae in the internal (mucosal) surface of the proventricular, which the mucosal surface of the proventricular was smooth, these muscular folds were wide near the gizzard while narrow toward the esophagus (Fig. 4). This results in agreement with [14]. Who showed the proventriculus in

Elanus caeruleus was thick-walled and spindle or cone-shaped [12]. Who documented an proventricular was dark brown and had well-developed longitudinal muscular folds separated from the ventricular stomach by very weak constriction and there was no clear division internally as there was no demarcation line or space (isthmus) between proventricular and ventricular.

3.2 Morphological Study of Gizzard in Dove and Buzzard

The present work revealed that the mean ratio of gizzard length to body length in dove was (10.40%) which is longer and differs significantly at level ($p < 0.05$) than that of buzzard (10.37%) although the mean length of gizzard in dove about 2.29 ± 0.11 cm and in buzzard about 4.46 ± 0.14 cm. The result of the current study showed that the mean ratio of gizzard weight to body weight in dove was (2.9%) which is significantly higher than that ratio in buzzard (0.80%) regardless of the mean weight of gizzard in dove about 4.460 ± 0.067 gm and in buzzard about 6.480 ± 0.115 gm (Tables 1,2).

3.2.1 In dove

The gross morphology in this study revealed the gizzard is usually located towards the abdomen, at the bottom of the thoracic cavity, and at the abdominal inlet, between the liver lobes justly behind the live left lobe and connected with the duodenum (Fig. 1). The present study observed clear differences in the gross morphological structure of the ventriculus or gizzard which appeared as a disc or biconvex lens shape with an increase in size and thicker when full with food and a change in color from creamy to red-brown morphologically, the findings revealed that the gizzard was covered by few fatty tissue, and is lined with kaolin (keratohyalin material) that appear yellowish to green in color (Fig. 3). The gizzard formed by four smooth muscle layers are named according to the appearance and color as thick, thin, light and dark muscles. Also, these muscles are named according to the location as: (cranio-dorsal muscle, cranio-ventral muscle, caudo dorsal muscle, and caudo ventral muscle with crniodorsal blind sac and caudoventral blind sac. This result agrees with [15]. Who showed The gizzard was lined by yellowish-green tissue, the koilin took the irregular pleated pattern of longitudinal folds in *Columba palumbus*, while [16] explained the gizzard had grits inside.

Notably, the koilin membrane is highly folded and deeply grooved in cranio-dorsal and caudo-ventral directions bearing lamellate and protuberant micro-ridges that flank both troughs of the gizzard together with its surface epithelium [9].

Table 1. The body length (cm), the organ length (cm), and the ratio of organ length/body length in (dove) and (buzzard)

Bird	Body length mean \pm SE	Organ	Organ length mean \pm SE	Ratio
Dove	22 \pm 1.123	Proventriculus	2.30 \pm 0.070	10.45%
		Gizzard	2.29 \pm 0.11	10.40%
Buzzard	43 \pm 1.98	Proventriculus	3.42 \pm 0.058	7.95%
		Gizzard	4.46 \pm 0.14	10.37%

Table 2. The body weight (gm), the organ weight (gm) and the ratio of organ weight/body length in (dove) and (buzzard)

Bird	Body length mean \pm SE μ m	Organ	Organs weight mean \pm SE	Ratio
Dove	150 \pm 10	Proventriculus	2.10 \pm 0.078	1.40%
		Gizzard	4.460 \pm 0.067	2.97%
Buzzard	810 \pm 29.83	Proventriculus	3.30 \pm 0.130	0.40%
		Gizzard	6.480 \pm 0.115	0.8%

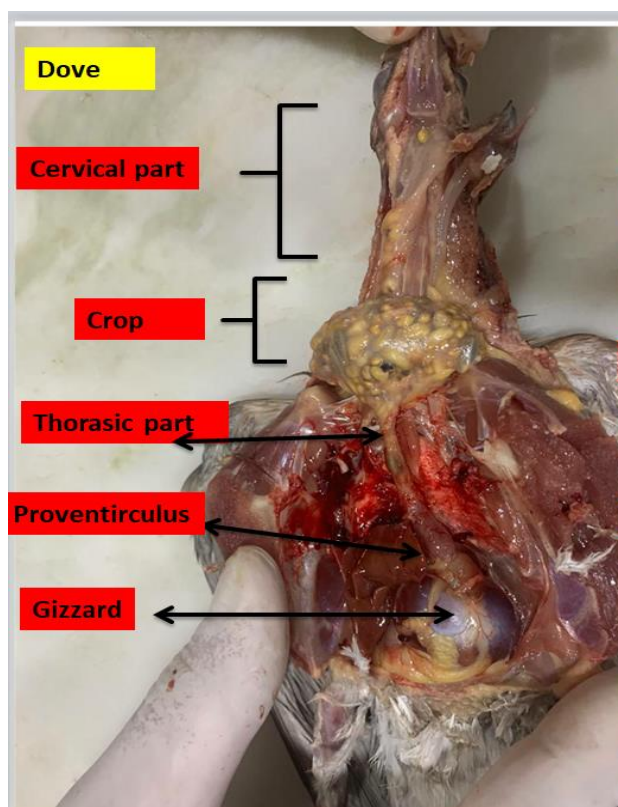


Fig. 1. Macrophotograph of the dissected thoracic and abdominal cavity after removing the heart in dove

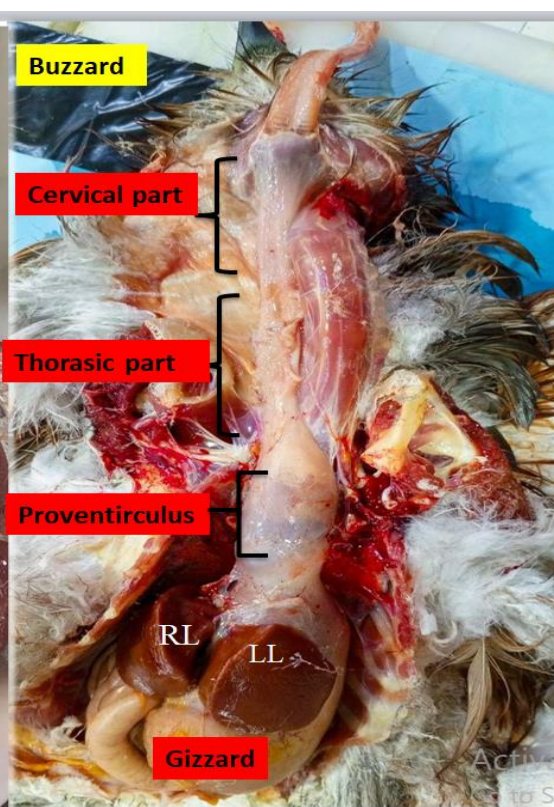


Fig. 2. Macrophotograph of the dissected showing internal surface after removing the heart in buzzard: (LL) left lobe liver, (RL) right lobe liver

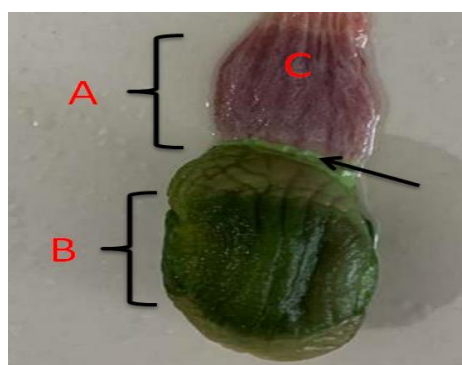


Fig. 3. Macro photograph of the dissected showing internal surface of (A) proventriculus, (B) gizzard, (C) proventriculus folds, (black arrow) gastric isthmus in dove

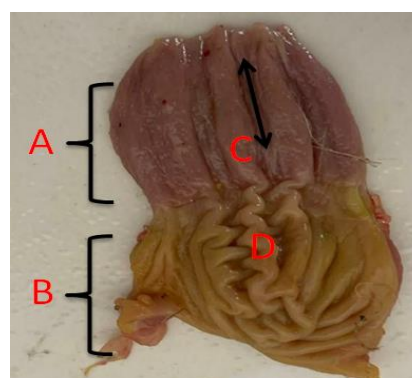


Fig. 4. macro photograph of the dissected showing internal surface of (A) proventriculus, (B) gizzard, (C) proventriculus folds, (black arrow) proventriculus groove, (D) ventriculus folds in buzzard

3.2.2 In buzzard

The gross morphology in this study revealed the gizzard is usually located dorsocaudally to liver lobes towards the abdomen cavity, at the dorsal part of the thoracic cavity, between the liver lobes, behind and connected with the duodenum, and appears larger than liver lobes (Fig. 2). The present study observed the gizzard shapes may range from pear to elongated, depending on the bird's unique anatomy and diet, the gizzard joined to the proventriculus cranially by the cardiac sphincter and joined to the hind gut or small intestine caudally by the pyloric sphincter and showed that the koilin layer of the internal surface due to the vertical and longitudinal pattern of the inner folds at the same time (Fig. 4) lining layer has very poor yellowish green pigment inside the gizzard and the present study did not recognize any grit inside the gizzard. This result agreement with [15]. Who found soft, elongated, spindle to pear shaped gizzard with a longitudinal outer groove on its surface in the barn owl (*Tyto alba*). In addition, the proventriculus and ventriculus form one large pear-shaped cavity in the common buzzard (*Buteo Buteo*) [17]. Also, this result agrees with [18]. Who finding the gizzard in the black-winged kite (*Elanus caeruleus*) was pear in shape with inner grooves on its surface; and that the koilin layer was very thin with poor yellowish-green pigment inside the gizzard.

4. CONCLUSION

Overall, depending on the unique bird's anatomy and the diet programs, there are changes in the inner surface of the organs of Dove and Buzzard.

DISCLAIMER (ARTIFICIAL INTELLIGENCE)

Author(s) hereby declare that NO generative AI technologies such as Large Language Models (ChatGPT, COPILOT, etc) and text-to-image generators have been used during writing or editing of manuscripts.

COMPETING INTERESTS

Authors have declared that no competing interests exist.

REFERENCES

1. Salem HM, Saad AM, Soliman SM, Selim S, Mosa WFA, Ahmed AE, Al Jaouni SK, Almuhayawi MS, Abd El-Hack ME, El-Tarabily KA, El-Saadony MT. Ameliorative avian gut environment and bird productivity through the application of safe antibiotics alternatives: a comprehensive review. *Poultry Science*. 2023;102(9).
2. Ibrahim IA, Mokhtar DM, Fadel S. The morphological development of the proventriculus of Dandarawi chick: Light and electron microscopical studies. *Morphologie*. 2020;104(344).
3. Al-Janabi QAA, Hamed LN, Ibraheem AK. Effects of Nano-Fipronil on Male Rats' Biochemical, Liver, and Renal Functions. In *IOP Conference Series: Earth and Environmental Science*. IOP Publishing. 2023;1259(1):012033.
4. Huang R, Li L, Song B, Lyu Y, Wu B. Appearance and digestive system comparison of *lonchura striata* and *copsychus saularis*: Searching for the

- effect of staple feeding ingredients on avian morphology. *Revista Brasileira de Ciencia Avicola / Brazilian Journal of Poultry Science*. 2020; 22(4).
5. Proszkowiec-Weglarz, M. Gastrointestinal anatomy and physiology. In *Sturkie's Avian Physiology Academic Press*. 2022; 485-527.
 6. Sensoy, I. A review on the food digestion in the digestive tract and the used in vitro models. *Current research in food science*. 2021;(4)308-319.
 7. Al-Janabi1 QAA, Abdulhay HS. Effect of inhalation exposure to nano-imidacloprid on liver and kidney functions in male rats. Third virtual international conference on environmental sciences, IOP conf. series: Earth and environmental science, al-qasim green university, college of environmental science, IRAQ. 2024;1325: 012021
 8. Bowen R. Digestive anatomy and physiology of birds. *VIVO Pathophysiology*; 2019.
 9. El-Mansi AA, El-Bealy EA, Rady AM, Abumandour MA, El-Badry DA. Macro-and microstructures of the digestive tract in the Eurasian collared dove, *Streptopelia decaocto* (Frivaldszky 1838): Adaptive interplay between structure and dietary niche. *Microscopy Research and Technique* 2021;84(12): 2837-2856.
 10. Madkour FA, Mohamed AA. Comparative anatomical studies on the glandular stomach of the rock pigeon (*Columba livia* targia) and the Egyptian laughing dove (*Streptopelia senegalensis aegyptiaca*). *Anatomia, histologia, embryologia*. 2019;48(1):53-63.
 11. AL-Taai SA. Morphological comparison of proventricular and gizzard in starling birds *Sturnus vulgaris* and pigeon *Columba livia*. *International Journal of Veterinary Sciences and Animal Husbandry*. 2022; 7(1):15-18.
 12. Abumandour MM. Histomorphological studies on the stomach of Eurasian hobby (Falconinae. *Falco subbuteo*, Linnaeus1758) and its relation with its feeding habits. *Life Science Journal*. 2014;11(7):809-819.
 13. Zhang H, Ge T, Peng S, Zhong S, Zhou Z. Microstructure Features of Proventriculus and Ultrastructure of the Gastric Gland Cells in Chinese Taihe Black-bone Silky Fowl (*Gallus gallus domesticus* Brisson). *Anatomia, Histologia, Embryologia*. 2016;45(1):1-8.
 14. Hamida Hamdi, Abdel-Wahab El-Ghareeb, Mostafa Zaher and Fathia AbuAmod. Anatomical, histological and histochemical adaptations of the avian alimentary canal to their food habits: II- *Elanus caeruleus*). *International Journal of Scientific & Engineering Research*; 2013.
 15. Al-Juboory RW, Dauod HA, Al-arajy AS. Comparative anatomical and histological study of the stomach in two Iraqi birds (*Columba palumbus* and *Tyto alba*). *Ibn AL-Haitham Journal For Pure and Applied Science*. 2017;29(2):1-12.
 16. Shawki N, Mahmoud F, Mohamed M. Seasonal variations of the digestive tract of Egyptian rock dove, *Columba livia*: Anatomical, histological and scanning electron microscopical studies. *Journal of Zoology*. 2021;50(1):60-97.
 17. Preja AI, Vlasciuc I, Damian, A. Macroscopic anatomical features of the digestive system in the common buzzard (*Buteo Buteo*); 2019.
 18. Rajab JM, Al-Sharqi SA, Abdelrahman SA. Comparative anatomical, histometrical, and histochemical study of esophagus between ring-necked parakeet (*Psittacula krameri*) and black-shouldered kite (*Elanus caeruleus*). *Iraqi Journal of Veterinary Sciences*. 2022;36(3):737-743.

Disclaimer/Publisher's Note: The statements, opinions and data contained in all publications are solely those of the individual author(s) and contributor(s) and not of the publisher and/or the editor(s). This publisher and/or the editor(s) disclaim responsibility for any injury to people or property resulting from any ideas, methods, instructions or products referred to in the content.

© Copyright (2024): Author(s). The licensee is the journal publisher. This is an Open Access article distributed under the terms of the Creative Commons Attribution License (<http://creativecommons.org/licenses/by/4.0>), which permits unrestricted use, distribution, and reproduction in any medium, provided the original work is properly cited.

Peer-review history:
The peer review history for this paper can be accessed here:
<https://prh.mbimph.com/review-history/3972>